



GROSS ANATOMICAL STUDIES ON THE PATTERN AND DENSITY OF THE TUNICA VASCULOSA TESTIS IN SOME FARM ANIMALS (BUFFALO, RAM, CAMEL, DONKEY AND RABBIT)

Elayat M. A., Khalil K. M., Farag F. M. and Rizk H.M

Department of Anatomy and Embryology, Faculty of Veterinary Medicine, Cairo University.

ABSTRACT

The aim of the study was to compare the pattern and density of the vascular layer of testis in some farm animals. The study was conducted on 50 specimens (10 for each species). The collected specimens are divided into two equal groups; the first group is used for gum milk latex injection while the other group is prepared for corrosive cast technique. The differences in the vascular pattern of the vascular tunic among the various species of farm animals are contributed to the architectural pattern of the marginal artery as well the mode of its termination so the current study suggest four patterns. The density of the tunica vasculosa in buffalo is pronounced in the distal third of both lateral and medial surfaces of the testis while it appears scanty in the proximal two third of both surfaces. In ram it is more pronounced than in buffalo while in camel the density of the tunica arteriosa testis is poor. In donkey the density of the tunica arteriosa testis is more pronounced in the distal two third of both surfaces of the testis. The density is poor and less pronounced in rabbit.

Keywords: Vascular layer, Testis, Ruminant, Donkey, Rabbit

(BVMJ-26(1):1-9, 2014)

1. INTRODUCTION

Tunica vasculosa is the vascular layer of the testis, consisting of a network of arterial and venous blood vessels. It embraces the inner surface of the tunica albuginea and the different septa in the interior of the testis, and therefore it forms an internal investment to all the spaces of which the parenchyma is composed. It is nevertheless very rare to find references on the pattern and density of the testicular vascular tunic among farm animals. The term, the tunica vasculosa testis, is named by Cooper (1830). Most of the studies on the vasculature of the testis among a large variety of animal species have attracted scientists' attention for many centuries. Harrison and Weiner (1949) in testis of mammals, Kirby (1953), Setchell

(1970), Godinho, Cardoso and Nogueira (1973), Ghoshal (1975), and Borthakur and Dhingra (1979) in ruminants. In addition the angioarchitecture of the arteries of the testis of the goat and buffalo was explained by Dhingra (1979). The study of the tunica vasculosa testis is extremely beneficial in the interpretation the role played by this part of vessels in the thermoregulatory mechanism of the testis. This is a highly efficient countercurrent heat exchanger in which the arterial blood is precooled before it reaches the testis, while the venous blood is warmed to body temperature before it returns to the heart. Also determination of different areas for biopsy in different species of farm animals is one of the most important benefits of the study of the tunica vasculosa testis.

2. MATERIALS AND METHODS

The study was conducted on ten specimens collected from each species of adult male farm animals. The collected specimens are inserted in normal saline solution at 37°C then they are divided into two equal groups and prepared for injection. The testicular artery was directly cannulated at the apex of the vascular cone and thoroughly washed by warm normal saline solution NaCl 0.9% containing a small addition of heparin (heparin calcium 5000 I.U.) to remove the clots and blood remaining in the vessels. The first group is used for latex gum milk injection according to the technique adopted by Neumaeyer (1932). While the other group is prepared for corrosive cast technique according to the procedure reported by Schummer (1951) using Epoxy (E 151 N20). After polymerization and hardening (1-2 weeks in room temperature), the specimens were corroded in strong acid solution (concentrated HCL) for 24 hours, washed in running tap water and then left to dry. The nomenclature used in this study was adapted to *Nomina anatomica veterinaria* fifth edition 2005.

3. RESULTS

The differences in the vascular pattern of the vascular tunic among the various species of farm animals suggest some degree of morphological specificity. In general these variations are contributed to the architectural pattern of the marginal artery as well the mode of its termination. Consequently it is convenient to describe the vascular pattern of this vessel among the different species of farm animals according to topographic base. The current study suggests four patterns.

3.1. *Pattern I: Buffalo and Ram:*

As the marginal part of the testicular artery in this species is too long in relation to the size and position of the testis the artery

performs secondary tortuosity along its wavy course. The degree of tortuosity is found more pronounced in ram than in buffalo. During its course along the Margo epididymidis, it pursues 2-3 windings before its termination. On a level of junction between the proximal $\frac{3}{4}$ and distal $\frac{1}{4}$ of the epididymal border of testis it forms a sigmoid curve then soon bifurcates into two equal Branches named according to their distribution as lateral and medial testicular arteries. On approaching the tail extremity of the testis the lateral and medial testicular arteries turn around the tail extremity forming 2-3 spiral windings then proceed in a dorsolateral and dorsomedial direction to both surfaces of the testis respectively. Both arteries divide to 7-9 smaller branches of second order that extend in a wavy manner dorsally and cranially toward the Margo epididymidis these branches are closely adherent to each other forming the tunica arteriosa testis. This tunic occupies a superficial position in the tunica albuginea testis under cover of the vaginal tunic. In buffalo the density of the tunica vasculosa is pronounced in the distal third of both lateral and medial surfaces of the testis while it appears scanty in the proximal two third of both surfaces. In ram it is more pronounced than in buffalo. It embraces nearly the entire surface and borders of the gland (Fig. 1/A, B, C - 2/A, B, C).

3.2. *Pattern II: Camel:*

The marginal part of the testicular artery during its course along the epididymal border it forms several wide helical windings for 4-5 times. On reaching the tail extremity of the testis it turns cranially then ascends on the free border for 2-3cm then terminates by 2-3 branches; lateral, cranial and medial testicular arteries. The cranial testicular branch appears as the direct continuation of the parent vessels extending proximally along the free border of the testis where it is divided into 3-4 branches that ramify in the

Margo liber. The lateral and medial testicular branches are equivalent to the preceding species but they are smaller and ramify in both surfaces of the testis in a dichotomy fashion. The vascular tunic is located at the middle of the tunica albuginea formed of loosely arranged blood vessels that scattered in wavy courses on the distal third of lateral surface and the free border of the testis. The density of the tunica arteriosa testis is poor in camel (Fig. 3/A).

3.3. Pattern III: Donkey:

The vascular pattern of this species is quietly specified and different. The pars marginalis of the testicular artery encircles the testicular circumference completely along its both borders. This arrangement begins at the head pole of the testis, extending caudally along the Margo epididymidis to reach the tail extremity where it is sharply bend cranially to the reverse direction and continues cranially along the Margo liber. On approaching the head extremity of the testis it terminates by several rami that pierce the testicular parenchyma. During its course along both borders of the testis it gives off several descending and ascending testicular branches (7-9 in number) which ramify in a zigzag like manner in both surfaces of the testis. The ascending branches are larger in length and caliber than the descending ones. The tunica vasculosa testis lies in the middle of the tunica albuginea. It appears as widely meshed network of vascular plexus formed of fine anastomotic branches derived from the ascending and descending testicular rami. The density of the tunica arteriosa testis is more pronounced in the distal two third of both surfaces of the testis (Fig. 4/A, B).

3.4. Pattern IV: Rabbit:

Unlike the preceding pattern the testicular artery wraps the testis twice instead of once. This arrangement is exclusively specified for

this species. Hence the marginal part of the testicular artery begins near the head extremity of the testis, extending caudally to the tail pole around which it turns cranially along the Margo liber to reach the head pole. Here the artery begins the second circle by passing caudally parallel to the epididymal border to reach the tail pole hence double marginal arteries are formed (Aa. marginalis dorsalis). On reaching the tail pole the artery bends down and soon divided into two equal branches that proceeded craniade toward the head pole parallel to the already existed one. Thus three marginal arteries appear along the Margo liber (Aa. marginales ventrales). These arteries have the same dimensions and extend cranially in a close parallel apposition along the whole length of the Margo liber testis. The vascular tunic is superficially located in the white tunic formed of several anastomotic rami between the arteries of the free and epididymal margins. The distal two third of both surfaces of the testis is embraced by the tunica vasculosa testis which has loosely arranged plexus, formed of a widely meshed vascular network. These anastomotic branches are very delicate so the density is poor and less pronounced (Fig. 5/A, B).

3.5. Rami parenchymales:

The parenchymal branches are 15-20 slender delicate vessels arise from the tunica arteriosa testis along the whole surface of the testis. They leave their origin and run through the texture of the testicular parenchyma in a radiating fashion toward the mediastinum testis as Rami centripetales parenchymales. On reaching the mediastinum they turn upon themselves and return in an opposite direction parallel to the centripetal ones as Rami centrifugals parenchymales. They are independent vessels without apparent anastomoses with the neighboring vessels.

The pattern and density of the tunica vasculosa testis in some farm animals

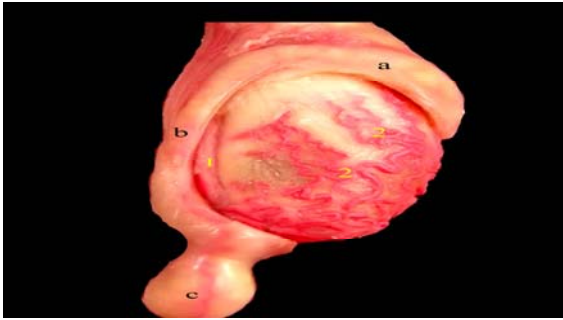


Fig. 1/A: A photograph of buffalo's right testis showing the density of the tunica arteriosa testis (latex injection technique). a - Caput epididymidis. b - Corpus epididymidis. c - Cauda epididymidis. 1 - Pars marginalis of a. testicularis 2 - Tunica arteriosa testis

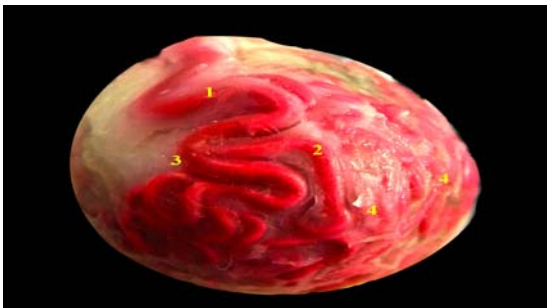


Fig. 1/B: A photographs of buffalo testis taken at the extrimitas caudata testis showing the mode of division of the pars marginalis (Latex injection technique). 1 - Pars marginalis of a. testicularis. 2 - Ramus lateralis of Pars marginalis of a. testicularis. 3 - Ramus medialis of Pars marginalis of a. testicularis. 4 - Tunica arteriosa testis

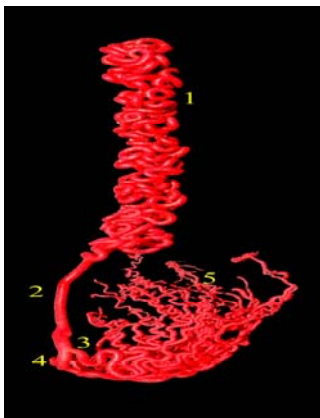


Fig. 1/C: A corrosive cast of Buffalo's testis showing the distribution of the Arteria testicularis (Epoxy injection technique). 1 - Pars funicularis of a. testicularis. 2 - Pars marginalis of a. testicularis. 3 - A. testicularis lateralis of Pars marginalis of a.

testicularis. 4 - A. testicularis medialis of Pars marginalis of a. testicularis. 5 - Tunica arteriosa testis

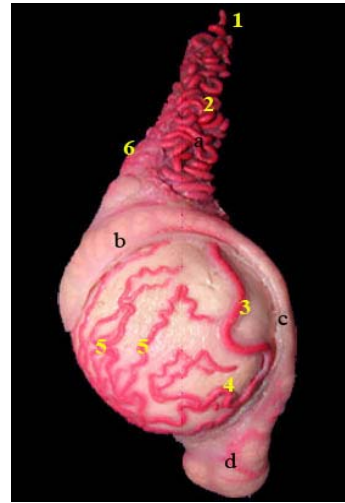


Fig. 2/A: A Photograph of Ram's left testis showing the distribution of the Arteria testicularis (Latex injection technique). a - Conus vascularis. b - Caput epididymidis c - Corpus epididymidis. d - Cauda epididymidis 1 - Arteria testicularis. 2 - Pars funicularis of a. testicularis. 3 - Pars marginalis of a. testicularis. 4 - A. testicularis lateralis. 5 - Tunica arteriosa testis. 6 - Arteria caput epididymidis.

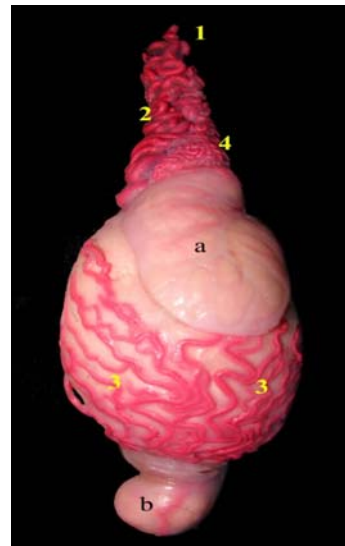


Fig. 2/B: A photograph of Ram's testis showing the density of the tunica arteriosa testis (latex injection technique). a - Conus vascularis. b - Caput epididymidis. c - Cauda epididymidis. 1 - Arteria testicularis. 2 - Pars funicularis. 3 - Tunica arteriosa testis. 4 - Arteria caput epididymidis.

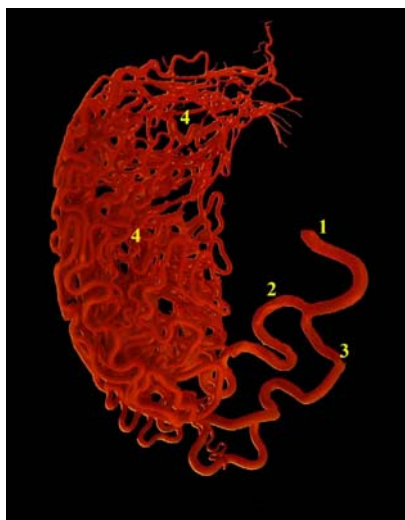


Fig. 2/C: A Corrosive arterial cast of Ram's left testis showing the density of the tunica arteriosa testis (Epoxy injection technique).1- Pars marginalis of A.testicularis.2- Ramus lateralis of Pars marginalis of a. testicularis. 3- Ramus medialis of Pars marginalis of a. testicularis. 4-Tunica arteriosa testis.

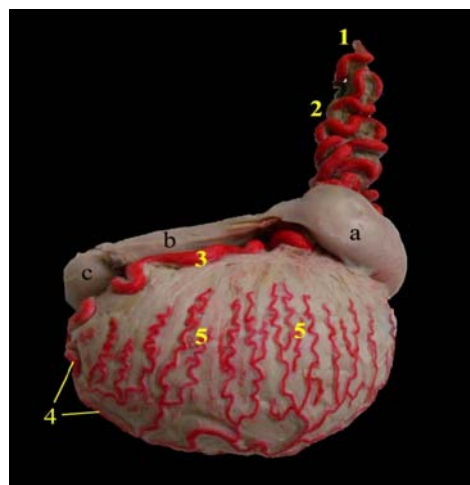


Fig. 4/A: A photograph of donkey's right testis showing the distribution of the testicular artery and density of tunica arteriosa testis. (Latex injection technique).a- Caput epididymidis b- Corpus epididymidis. c- Cauda epididymidis 1- A. testicularis.2- Pars funicularis of a. testicularis.3- Pars marginalis of a. testicularis. 4- Pars marginalis along the margo liber.5- Tunica arteriosa testis

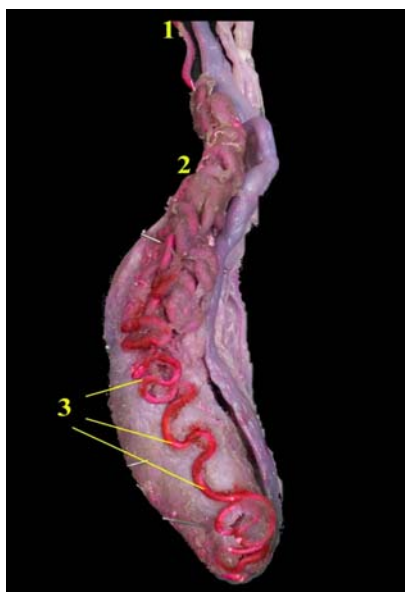

Fig. 3/A: A photograph of camel's right testis showing the distribution of the testicular artery. (Latex injection technique).1- Arteria testicularis.2- Pars funicularis of a. testicularis.3- Pars marginalis of a. testicularis

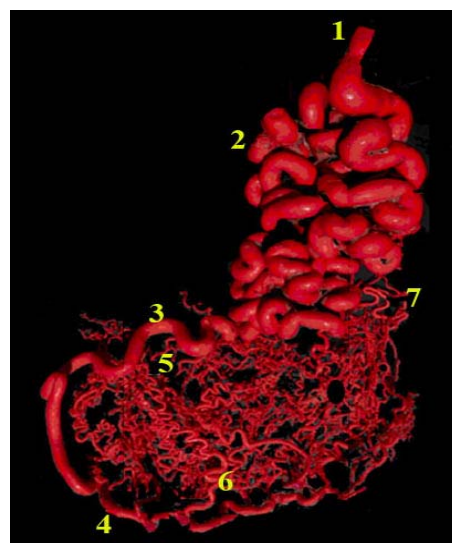


Fig. 4/B: A Corrosive arterial cast of Donkey's testis showing the architectural pattern of the testicular artery (Epoxy injection technique).1-A.testicularis 2. Funicular part of testicular artery 3-Pars Marginalis 4- Pars marginalis along margo liber.5-Descending branches of Pars Marginalis. 6- Ascending branches of Pars Marginalis. 7- A. caput epididymidis

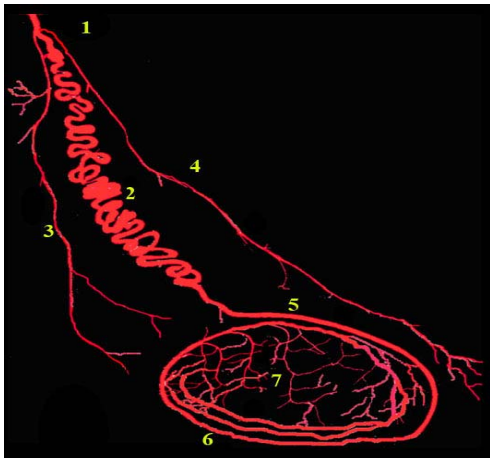


Fig. 5/A: A Corrosive arterial cast of Rabbit's testis showing the architectural pattern of the testicular artery (Epoxy injection technique). 1- A. testicularis. 2- Pars funicularis. 3- A. caput epididymidis. 4- A. cauda epididymidis. 5- Pars marginalis dorsalis. 6- Pars marginalis ventralis. 7- Tunica arteriosa testis.

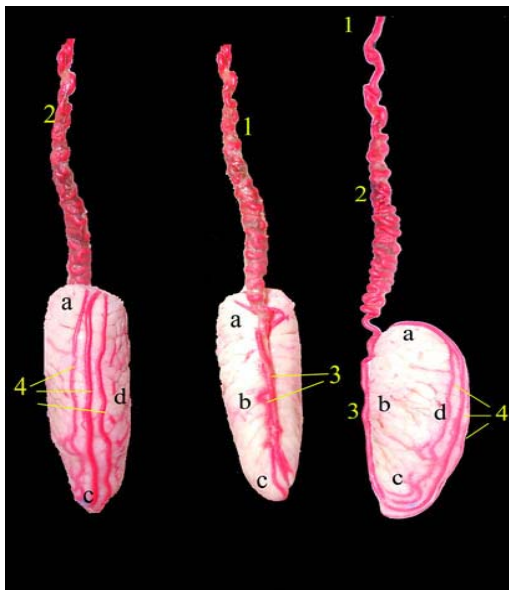


Fig. 5/B: A photograph of Rabbit's testis showing the architecture pattern of testicular artery. (Latex injection technique). a- Extrimitas capitata testis. b- Margo epididymidis. c- Extrimitas caudate testis. d- Margo liber. 1- A. testicularis. 2- Pars funicularis. 3- Pars marginalis dorsalis. 4- Pars marginalis ventralis

4. DISCUSSION

The architectural pattern and morphometry of the testicular arteries showed considerable differences between the studied species of farm animals. The vascular pattern of the testis had showed species variations among all species of mammals Harrison and Weiner (1949).

According to the course and mode of termination of the pars marginalis of the arteria testicularis, the present work could classify the vascular pattern into four patterns.

The first pattern is present in buffalo and ram. It is the most complicated one in which the vessel showed a highly convoluted pattern in the cord and gonad. On reached the tail pole of the testis it gave off two terminal Branches. These findings are in agreement with those of earlier authors. Harrison (1949) in mammals, Abu-Zaid and Gad (1999) in goat, El-Gaafary et al., (1980) in buffalo and Hees et al., (1984) in bovine.

The second pattern was described in camel. The testicular artery showed several wide helical windings for 4-5 times on the cord and gonad. On reaching the extrimitate caudate testis it turned cranially then dorsally to approach the free border and terminated by three branches; lateral, cranial and medial testicular arteries. El-Gaafary and Aly (1977). in camel stated that the pars marginalis showed either a straight or serpentine course and gave two branches only; the lateral and medial testicular arteries while Osman et al., (1979) revealed that this vessel was compactly coiled on approaching the testis and then became less tortuous along the attached border. Also they added that this vessel is terminated near the tail extremity by 2-4 branches.

The third pattern which was exclusively specified for donkey species, the pars marginalis of the testicular artery encircled the testis completely along its both borders. Several descending and ascending testicular

branches (7-9 in number) were given off from this circle and ramified in a zigzag like manner in both surfaces of the testis. Similar division was given by Fehlings and Pohlmeier (1978).

In the fourth pattern the pars marginal of the testicular artery wrapping the testis twice and this arrangement was also exclusively specified for rabbit species. Similar observation was emphasized in rabbit by Harrison and Weiner (1949) and Rajtová and Danko (2001). However this arrangement was not mentioned by Mc Laughlin (1972) in the same species. On the other hand, neither Harrison (1949) nor Chubb and Desjardins (1982) have reported the intra-parenchymal arrangement of such vessel in the rabbit.

Concerning the terminal division of the marginal part of the testicular artery, the present work has described two main branches in buffalo and ram named as lateral and medial testicular arteries that spread over the lateral and medial surfaces of the testis. Similar division was given in bull Polguy *et al.*, (2008), in camel El-Gaafary and Aly (1977), in goat Abu-Zaid and Gad (1999) and in buffalo El-Gaafary *et al.*, (1980) who named them as lateral and caudal branches.

In camel, the current work gave off three terminal branches for the terminal division of the pars marginalis, the result, which disagreed with that of El-Gaafary, and Aly (1977) who gave two branches only in the same animal.

In rabbit, the present work gave an exclusive pattern of arrangement, which was specified for this species. Hence the marginal part of the testicular artery has twice encircled the surface of the testis before its termination into two main branches. Similar findings for the termination of the marginal artery in rabbit were reported by Harrison (1949), Harrison and Weiner (1949), while in Mc Laughlin (1972) study such arrangement has not mentioned in the same animal.

Moreover, our result has referred to the presence of three arteries run side by side along the free border of the testis. A similar observation in rabbits was also recorded by Harrison (1949). Harrison and Weiner (1949) considered the circular arrangement of the vessel to be a part of thermoregulatory mechanism of the testis.

One of the most interesting and important finding of this study was the determination of different areas for biopsy in different species of farm animals to minimize bleeding risk. Similar to the findings of El - Gaafary, Aly and El- Ayat (1980) in buffalo and Polguy *et al.*, (2011).

5. REFERENCES

1. Abu-Zaid, R.M. and Gad, M.R. 1999. Goat Testicular Blood Supply: A Study by Corrosion Cast and Angiography. *Journal of the Egyptian veterinary medical association.* 59: 6.
2. Borthakur, S. and Dhingra, L.D. 1979. Anatomical studies on the blood vessels of the testis in buffalo (*Bubalus bubalis*) *Indian J. Anim. Sci.* 49, 266.
3. Chubb, C. and Desjardins, C. 1982. Vasculature of the mouse, rat, and rabbit testis-epididymis. *Am J Anat* 165:357-372.
4. Cooper, A. 1830. On the anatomy of the testis. Observations on the structure and diseases of the testis. 1. London, UK: Longman. 1-55.
5. Dhingra, L. 1979. Angiarchitecture of the arteries of the testis of goat (*Capra aegagrus*). *Zbl. Vet. Med. C. Anat. Histol. Embryol.* 8: 193-199.
6. Dhingra, L. 1979. Angioarchitecture of the buffalo testis. *Anatomischer Anzeiger* 146: 60-68.
7. El-Gaafary, M.A. and Aly, A.A. 1977. Anatomical studies on the arterial supply of the testis and epididymis of the dromedary camel. *Assiut Veterinary Medical. J.* 4: 46-52.

The pattern and density of the tunica vasculosa testis in some farm animals

8. El-Gaafary, M.A., Aly A.E. and El-Ayat, M.A. 1980. Morphological studies on the testicular artery in the Egyptian water buffalo (*Bos Bubalis* L.). The Egyptian veterinary medical journal. 28: 464-472.
9. Fehlings, K. and Pohlmeier, K. 1978. Die Arteria testicularis und ihre Aufzweigung im Hoden und Nebenhoden des Esels (*Equus africanus* f. *asinus*). Korrosionsanatomische und rontgenologische Untersuchungen. Zbl. Vet. Med. C. Anat. Histol. Embryol. 7: 74.
10. Ghoshal, N.G. 1975. Heart and arteries. In: "Sisson and Grossman's The Anatomy of Domestic Animals (GETTY, R.)". Vol. I, p. 985. 5th edition, W. B. Sanders Co., Philadelphia.
11. Godinho, H.P., Cardoso, F.M. and Noguerira, J.C. 1973. Pattern and parenchymal ramification of the testicular artery in some ruminants. Anat. Anz. 133: 118-124. Gomes eds.), pp. 39-85. Academic Press New York.
12. Harrison, R.G. and Weiner, J.S. 1949. Vascular patterns of the mammalian testis and their functional significance. Journal of Experimental Biology 26: 304-316.
13. Harrison, R.G. 1949. The distribution of the vassal and cremasteric arteries to the testis and their functional importance. Journal of Anatomy, 83: 267-282.
14. Hees, H., Leiser, R., Kohler, T. and Wrobel, K. 1984. Vascular morphology of the bovine spermatic cord and testis. Light- and scanning electron-microscopic studies on the testicular artery and pampiniform plexus. Cell Tissue Res 237:31-38.
15. Kirby, A. 1953. Observations on the blood supply of the bull testis. Br. Vet. J. 109: 464-472.
16. Mc Laughlin, C.H. 1972. Laboratory Anatomy of the Rabbit. W.M.C. Brown Co. Publishers, Dubuque, Yowa, 112 pp.
17. Nomina Anatomica veterinaria 2005. Vet. Anat. Nomenclature of the world association vet.anat., 5th edition.
18. Neumaeyer, L. 1932. Cummepprepamte fur injektion zwecke Z. Wiss. Mikrosplep. Technick. 49, 194.
19. Osman, D.I., Tingari, MD. and Moniem, K.A. 1979. Vascular supply of the testis of the camel (*Camelus dromedarius*). Acta Anat 104:16-22.
20. Polgaj, M., Jeźdrzejewski, K.S. and Bolanowski, W. 2008. Comparison of blood vessels complex of human and bovine masculine gonad. Folia Morphologica 67, 87-97.
21. Polgaj, M., Sopinski, M., Jeźdrzejewski, K.S., Bolanowski, W. and Topol, M. 2011. Angioarchitecture of the bovine tunica albuginea vascular complex – A corrosive and histological study. Research in Veterinary Science journal 181-187.
22. Rajtová, V. and Danko, J. 2001. Vasculature of testis, epididymis and ductus deferens of rabbit. The arteries Acta Vet. Brno. 70: 3- 7.
23. Schummer, A. 1951. Vereirfechts plastoid viorrasyon verfahren. Anat. Anna., 98: 288-290.
24. Setchell, B.P. 1970. The secretion of fluid by the testes of rats, ram and goats with some observations on the effect of age, cryptorchidism and hypophysictomy. J. Reprod. Fertil., 23: 79-85.



دراسات تشريحية عن نمط وكثافة طبقة الأوعية الدموية (الغلالة الوعائية) للخصية في بعض حيوانات المزرعة (الجاموس ، الكبش ، الجمل ، الحمار والأرنب).

مدحت أحمد العياط ، كريم محمد خليل ، فؤاد محمد فرج ، حمدي رزق محمد
قسم التشريخ والأجنة - كلية الطب البيطري - جامعة القاهرة

الملخص العربي

الهدف من هذه الدراسة هو مقارنة نمط وكثافة طبقة الأوعية الدموية (الغلالة الوعائية) للخصية في بعض حيوانات المزرعة. وقد أجريت الدراسة على 50 عينة (10 عينات لكل نوع). وقسمت العينات التي تم جمعها الى مجموعتين متساويتين، المجموعة الأولى أستخدمت للحقن باللاتكس المطاط في حين تم اعداد المجموعة الثانية لعمل قوالب للأوعية. ساهم نمط التكوين الوعائي للشريان الهامشي فضلا الى طريقة انتهاء الشريان في الأختلافات بين نمط الأوعية الدموية للطبقة الوعائية للخصية في أنواع حيوانات المزرعة. ولذلك فإن الدراسة الحالية أقترح أربع انماط. كثافة الطبقة الوعائية في الجاموس تتضح بشدة في الثلث السفلى على كل من سطحى الخصية بينما تبدو هزيلة في الثلثين العلويين لكل سطح. في الكبش هي أكثر وضوحا مما كانت عليه في الجاموس بينما في الجمل فكثافة الطبقة الوعائية للخصية فقيرة. في الحمار كثافة الطبقة الوعائية تكون أكثر وضوحا في الثلثين السفليين من سطحى الخصية. وكثافتها فقيرة وأقل وضوحا في الأرنب.

(مجلة بنها للعلوم الطبية البيطرية: عدد 26(1):1-9، مارس 2014)